

BIOTECH BP Total Shoulder System

Surgical Technique



Biotech GmbH
Hauptstraße 113.
56598 Rheinbrohl Germany
Tel : +49 2635 92221-0
Email : office-de@biotech-medical.net
www.biotech-medical.com



BIOTECH

REF:
VB-002-PROSP-ST

Revision
2

Publication date :
01.04.2022.

CE1011

“Movement is Life”

INDICATIONS AND CONTRA INDICATIONS

INDICATIONS

Pain and disability arising from the gleno-humeral joint as a result of:

- Osteoarthritis.
- Post-traumatic arthritis.
- Rheumatoid arthritis and other inflammatory arthritides.
- Osteonecrosis.
- Gleno-humeral deformity with secondary arthritis.
- Rotator cuff tear arthropathy

In case the rotator cuff tendons are not reconstructible, hemiarthroplasty with a large humeral head is used.

CONTRAINDICATIONS

- Active infection present in the region of the shoulder (in the past 2 years).
- A history of habitual instability is a relative contraindication.
- Paralysis of the rotator cuff muscles or the deltoid muscle.
- Charcot disease of the shoulder

EARLY AND LATE FRACTURE MANAGEMENT

The prosthesis has an articulating humeral head, which allows for its use as a hemiarthroplasty as well as a total shoulder replacement. The adjustable head heights allow for appropriate tensioning of the rotator cuff muscles; this is particularly difficult in the late fracture and malunion cases.

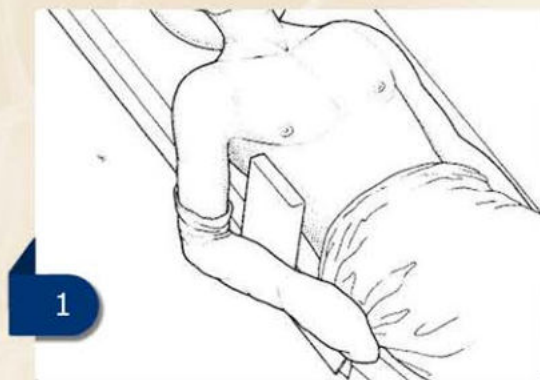
PREOPERATIVE PLANNING

- It is essential to have good quality AP and axial radiographs of the shoulder.
- a CT scan will provide detailed image of the

bones in particular the glenoid and allow the surgeon to plan the operation and the need for bone grafting, in the severely damaged shoulder particularly in rheumatoid arthritis.

PATIENT POSITIONING

The patient should be placed in a semi sitting or beach chair position at about 45 degrees of head-up tilt. It is important to allow hyperextension of the arm during surgery to facilitate insertion of the humeral component (1).

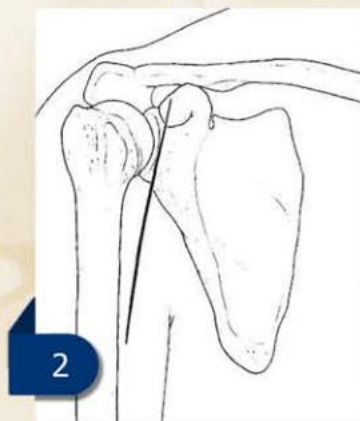


THE SURGICAL APPROACH FOR HEMIARTHROPLASTY

This approach provides an exposure of the front of the gleno-humeral joint, the humeral head and the upper humeral shaft.

INCISION

An incision of 15 cm is made from the clavicle down across the tip of the coracoid. It should be continued in a straight line to the anterior border of the insertion of the deltoid (2).



APPROACH

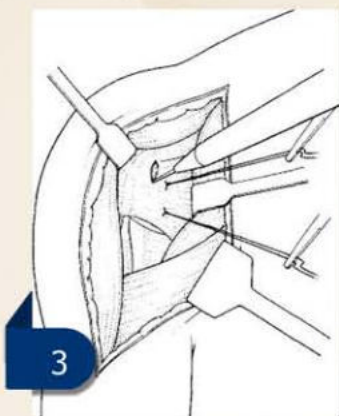
By appropriate cauterisation of its lateral branches in the deltopectoral groove, the cephalic vein is mobilised. The vein should be retracted medially and the deltoid is retracted laterally. Abduct the arm 40° to 60° and then incise the clavipectoral fascia.

Clear the subacromial space and place a broad elevator as a retractor beneath the acromion.

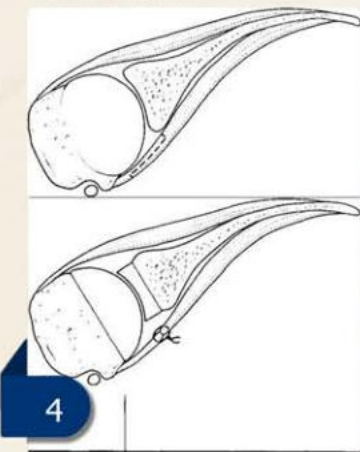
By dividing the proximal 2 cm of the insertion of pectoralis major improved exposure will be obtained at this stage.

Flex the shoulder and rotate it externally in order to facilitate coagulation of the anterior circumflex humeral vessels.

It is very important to insert stay sutures into the subscapularis muscle to control retraction. Divide the tendon 2 cm medial to the bicipital groove (3).



The subscapularis should be divided in an oblique or "Z" manner if it appears tight, to allow repair with lengthening of the tendon (4).



The joint capsule is then released anteriorly and inferiorly. Care should be taken to protect the axillary nerve with a blunt elevator where it passes through the quadrilateral space.

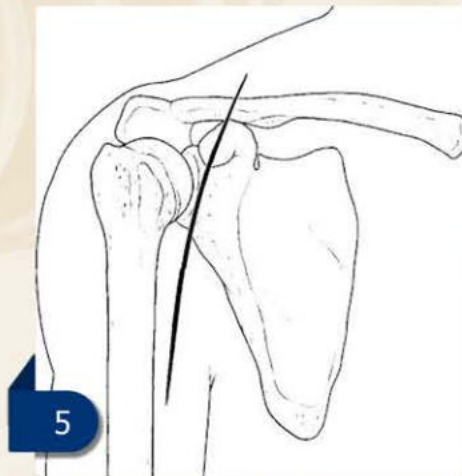
By external rotation and extension the gleno-humeral joint may now be dislocated anteriorly, allowing a full exposure of the humeral head and neck.

THE SURGICAL APPROACH FOR TOTAL SHOULDER ARTHROPLASTY

This approach allows a wide exposure of the whole of the front of the shoulder region, providing access to the gleno-humeral joint. It provides particularly good access to the face of the glenoid and to the humeral head (including the superior aspect of the head), the subacromial region and the humeral neck distally as far as the insertion of deltoid.

INCISION

Start an incision 12 cm long 2 cm above the clavicle and continue vertically down, across the tip of the coracoid and distally just lateral to the anterior axillary fold (5).



APPROACH

Locate the cephalic vein distally in the deltopectoral groove and dissect medially, ligating or cauterising its lateral branches.

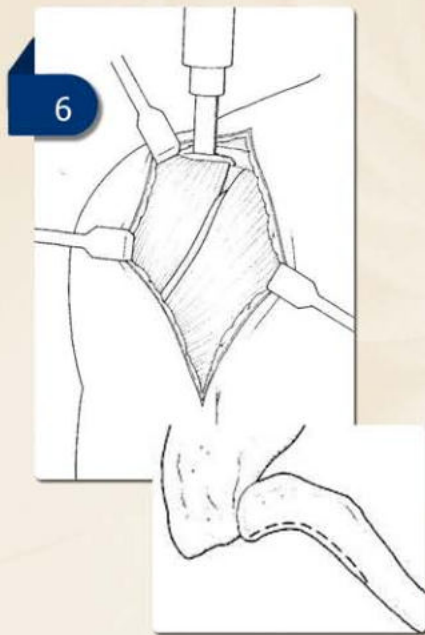
The vein may be ligated at the top and bottom of its exposed section, if the bleeding is too strong.

The lateral third of the clavicle is now exposed and the acromioclavicular joint identified using a needle to probe the joint space.

Now evide the periosteum lying over the lateral third of the clavicle longitudinally retaining the muscular attachments of the deltoid below and the trapezius above.

Osteomise the anterior one-third or less of the A-P width of the clavicle using an oscillating saw and cutting downwards, with a curved cut from the main part of the bone.

The saw cut is curved anteriorly and brought out of the clavicle both at the medial attachment of deltoid and just medial to the acromioclavicular joint (6).



The clavicular attachment of the deltoid remains attached firmly to the separated bony sliver. The split clavicle will initially fall apart without any leverage and the clavicular head of the deltoid can be gently reflected downwards and laterally. The cutting of a part of the coraco-clavicular ligament might be necessary in order to swing the anterior clavicle fragment forward and during the dissection there is always an artery, which needs to be cauterised.

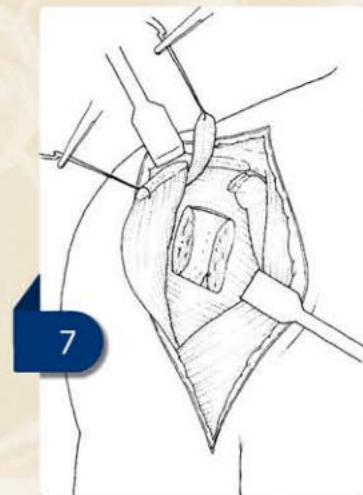
By dividing the coracoacromial ligament, which may be repaired later or excised, the rotator cuff may now be exposed

This approach involves osteotomising the lesser

tuberosity from the humeral head. By opening up the rotator interval (from the upper end of the bicipital groove to the base of the coracoid) carefully define the superior border of the subscapularis tendon, then by defining its lower edge and then identifying the medial edge of the bicipital groove which is exposed by using cautery without exposing the tendon of the long head of the biceps.

Perform the osteotomy with either an oscillating saw or with an osteotome directed into the centre of the humeral head initially, then levered to fracture off the lesser tuberosity, which is then retracted using stay sutures.

Instead of osteotomising the lesser tuberosity, the subscapularis can be divided 1 -2cm from its insertion with the medial part retracted medially using 2 stay sutures in order to protect the brachial plexus.

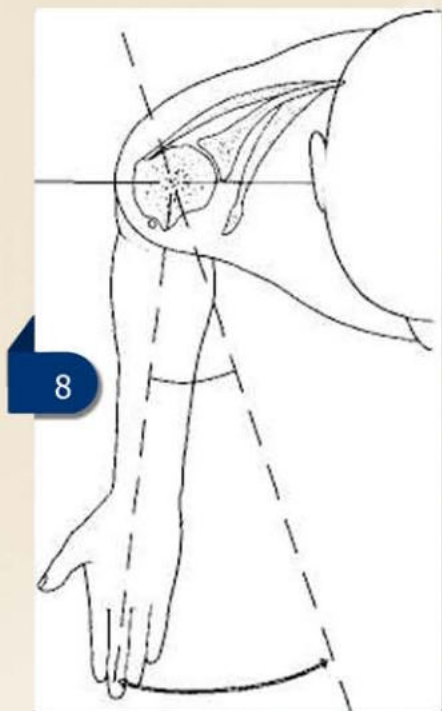


INITIAL HUMERAL PREPARATION

Assess the osteophytes before osteotomy of the humeral head, particularly inferiorly, which can be prominent in osteoarthritis. Place the arm in 90° of external rotation to allow the posterior slip of the supraspinatus and long head of biceps.

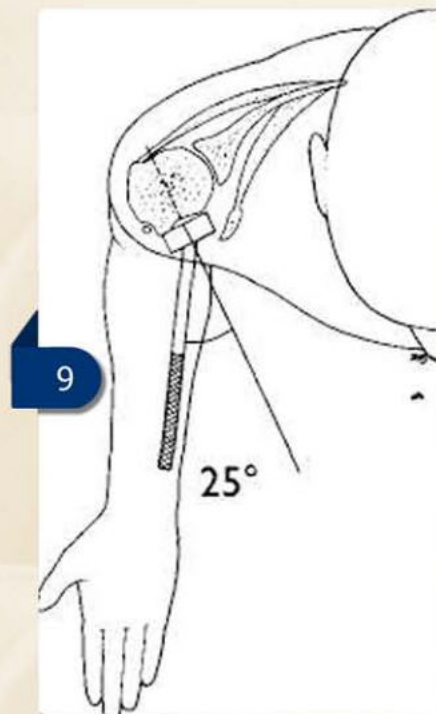
Protect the long head of biceps tendon before the resection of the head with a periosteal elevator placed under the tendon and over the humeral head.

The humeral head is usually in 25° to 30° of retroversion in relation to the shaft of the humerus and on average the centre of the humeral head lies about 5 mm posterior to the longitudinal axis of the humerus (8).



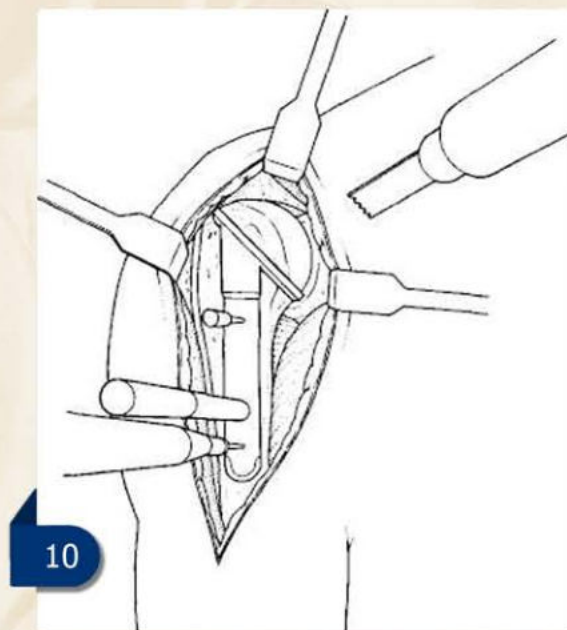
Carry out the humeral head osteotomy with the help of the **extramedullary humeral head resection guide** (left hand resection guide: 727-0008-0001, right hand resection guide: 727-0008-0002). It is possible to fix the humeral resection guide by 1 or 2 pins to the humeral shaft or it can be simply held in place using the alignment rod as a handle.

The **alignment rod** (727-0011-0000) on the guide determines the amount of retroversion of the humeral cut, the alignment rod is aligned parallel to the forearm when the elbow is flexed to 90°. The upper end of the cutting flange of the guide should be located medial to the attachment of the supraspinatus tendon to the greater tuberosity (9).



Perform the osteotomy with the help of an oscillating saw, taking care to ensure that the insertion point of the rotator cuff into the greater tuberosity is not included in the osteotomy -both superiorly and posteriorly.

The osteotomy can be performed in 2 slices, removing the major part of the articular surface first, re-assessing the cuff insertion and then removing a further part (10).



MOBILISING THE ROTATOR CUFF MUSCLES

Mobilisation should be carried out in all cases. The rotator cuff tendons and muscles (subscapularis in front and supraspinatus and infraspinatus behind) need to be mobilised both superficially and deep.

Separate the muscles superficially from the deltoid above and behind and the acromion superiorly with the help of blunt finger dissection and sharp dissection with scissors. By sharp dissection with a knife release the muscles deeply from the anterior and posterior glenoid rim and from the whole of the anterior neck of the scapula usually by blunt dissection using a periosteal elevator.

Thereby the length of the tendons will increase, particularly subscapularis, which may gain about 2 to 3 cms as a result of this dissection.

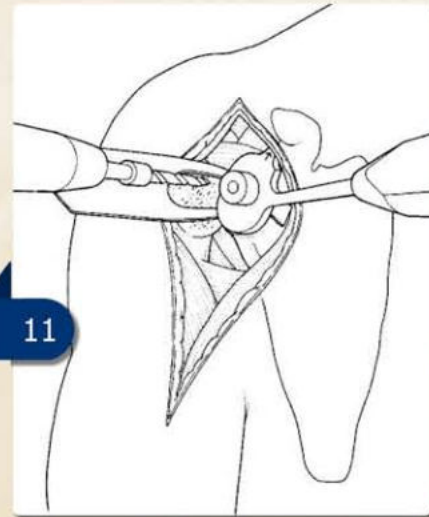
Finally repair of subscapularis, which can result in an improvement of external rotation in the order of 30° to 50°. The infraspinatus can be mobilised in a similar way.

GLENOID PREPARATION

Place the glenoid retractor behind the posterior glenoid rim and retract posteriorly, pushing the proximal humerus backwards. This will allow good access to the glenoid.

Remove any soft tissues obscuring the glenoid rim and any anterior and posterior osteophytes on the glenoid rim.

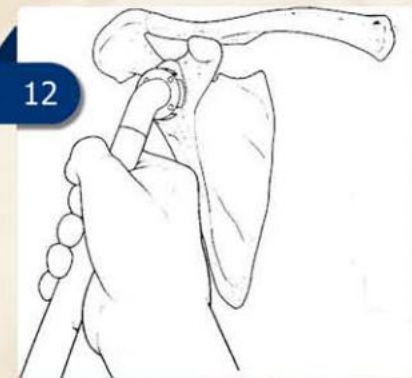
Hook the **glenoid positioner** (right hand glenoid positioner: 727-0019-0000, left hand glenoid positioner: 727-0019-0001) over the front rim of the glenoid and place it firmly on the glenoid surface with the marked arrow directed towards the base of the coracoid. Drill a hole in the centre of the glenoid with the help of the **5 mm drill bit** (727-0007-0005) (11).



By palpation of the front of the neck of the scapula, (which can also be visualised, if the subscapularis is retracted antero-medially) the AP alignment of the glenoid jig and drill can be directed.

It is advisable to drill very shallow hole first then remove the jig and confirm the location of the hole to be close to the centre of the glenoid. Then replace the jig and drill the hole to its full depth using the whole length of the drill down to its stop.

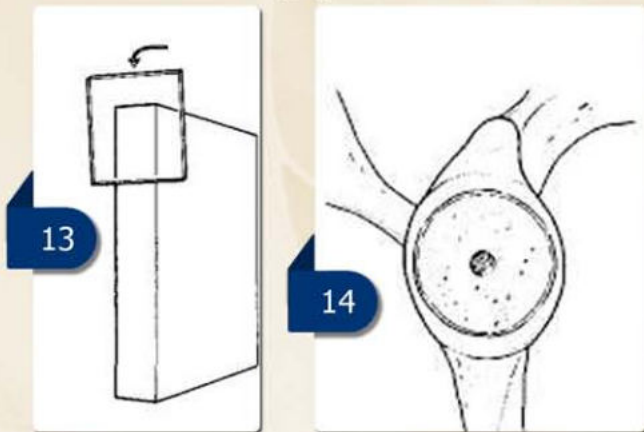
Insert the smaller diameter of the powered **glenoid reamer** (727-0021-0001) to the drill hole and create a flat recessed cut face centrally in the glenoid (12).



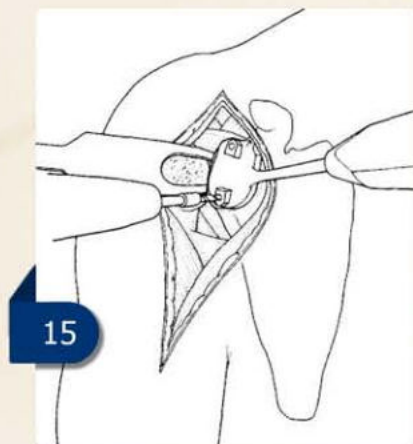
This peripheral rim of bone will allow the surgeon to evaluate, whether the desired amount of bone supero-inferiorly and antero-posteriorly has been taken. Define the exact direction for the reaming from the radiographs.

The aim is to produce a glenoid, facing either directly laterally or with a slight ownward tilt of up to 5° (13). Avoid preparing the glenoid in such a way that an upward tilt of the glenoid component is produced as this will cause reduction of the subacromial space because of superior migration of the head and might also result in a reduction of the range of movement of the shoulder. It is also necessary to check the AP direction of reaming based on the pre-operative radiographs, correcting any excessive retroversion or anteversion.

Complete the glenoid preparation with the help of the **larger glenoid cutter** (727-0001-0003), which will create a completely flat glenoid face resection, reamed down to bleeding subchondral bone (14).



The **glenoid alignment guide** (right hand glenoid alignment guide: 727-0008-0005, left hand glenoid alignment guide: 727-0008-0006) should be placed onto the central glenoid drill hole and pushed flat onto the reamed glenoid surface (15).

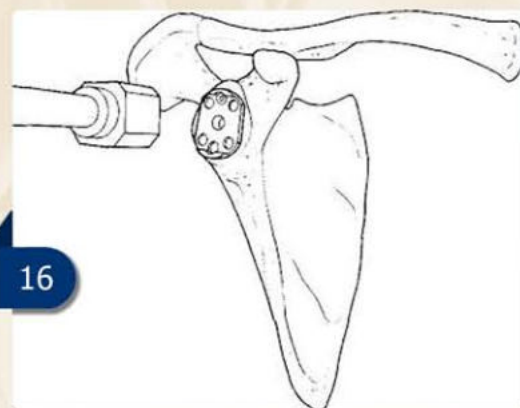


Direct the marked arrow towards the base of the coracoid process. Drill through both the superior and inferior holes on the guide using the **3mm drills** (727-0007-0003), to the full depth of the drill or until the drill is felt to perforate the cortical plate of the scapula.

It is important to confirm again the AP direction for drilling, which is guided again by the anterior neck of the scapula. Remove the glenoid alignment guide after drilling.

The **central stem tapered reamer guide** (727-0008-0004) should be placed onto the prepared glenoid surface and the **central stem reamer** (727-0021-0004) applied to enlarge the central hole to the correct depth and width to accept the peg on the back of the glenoid base plate.

Mount the modular glenoid metal tray to its **inserter** (727-0001-0004) and then insert it into the prepared area, impacting it with a hammer in the appropriate rotational position (16).

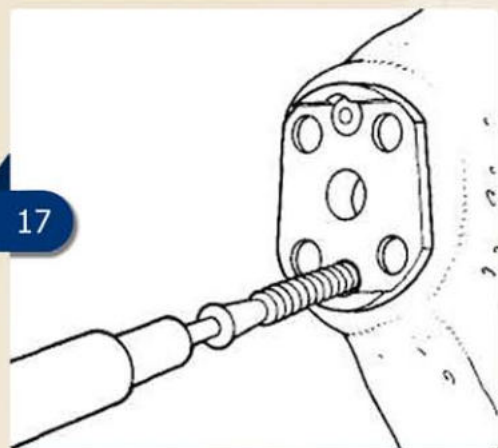


This is confirmed by directing the antero-superior lug or arrow towards the base of the coracoid. It is important to check at this stage that no soft tissue is pinched underneath the base plate.

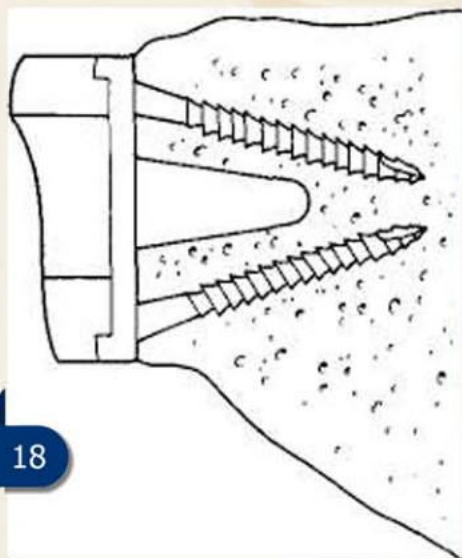
Drill the holes (if they were not pre-drilled earlier) through the holes in the glenoid base-plate.

Drill the holes (if they were not pre-drilled earlier) through the holes in the glenoid base-plate.

Once the metal tray is seated securely on the glenoid face, insert the self-tapping screws through the superior and inferior drill holes (17).



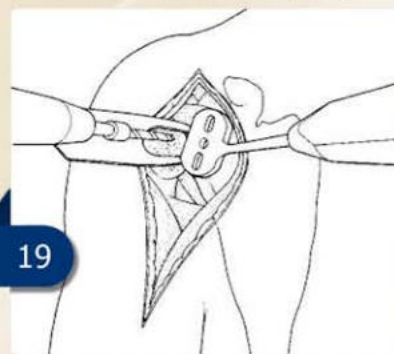
Insert the superior screw first and tighten it to the point of contact with the metal baseplate. The inferior screw should be inserted tightly and both screws should finally be re-tightened. These screws usually provide very firm fixation even in rheumatoid patients (18).



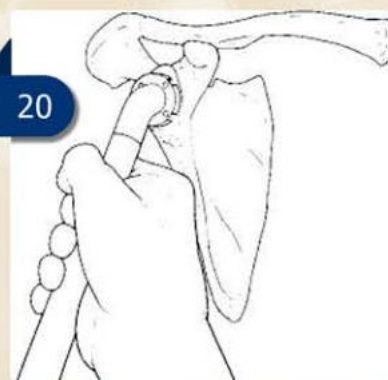Apply the **trial polyethylene glenoid insert** (727-0009-3003 – 727-0009-5005) to protect the baseplate and exchange it only for the definitive glenoid insert at the final stage, once the definitive humeral stem has been inserted.

GLENOID PREPARATION (cemented component)

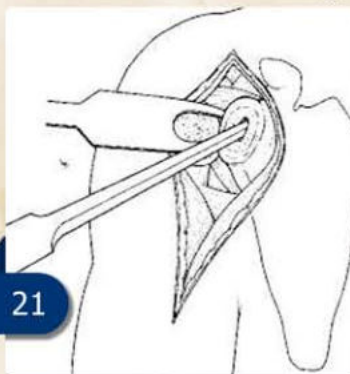
If a cemented polyethylene component is chosen, the size appropriate size is determined with the **glenoid template fin guide** (727-0008-0003). Drill a 3mm hole through the central hole of the fin guide (19).



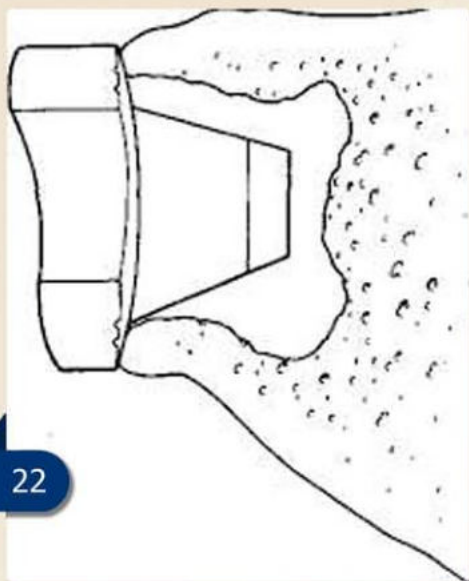Prepare the glenoid fossa using the **glenoid surface rasp** (727-0021-0002) (20).



To begin creating the glenoid fin dome use a high-speed burr. Then enlarge the slot to accept the glenoid fin with a glenoid fin rasp (727-0021-000). Use sequential curettes to undercut the glenoid dome and to accommodate the keel of the polyethylene component, and allow for better cement fixation (21).



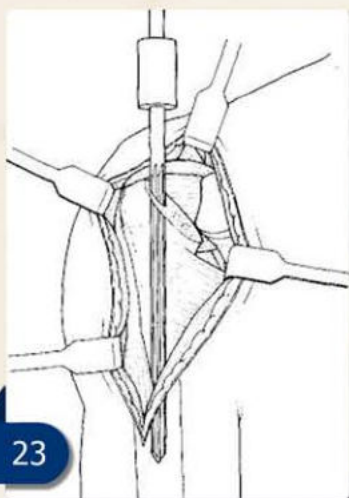
Before the cementing of the glenoid component clean the cortical cancellous surface. After that introduce the glenoid component into bone cement and ensure proper fixation. Remove all excess cement carefully removed (22).



FINAL HUMERAL PREPARATION

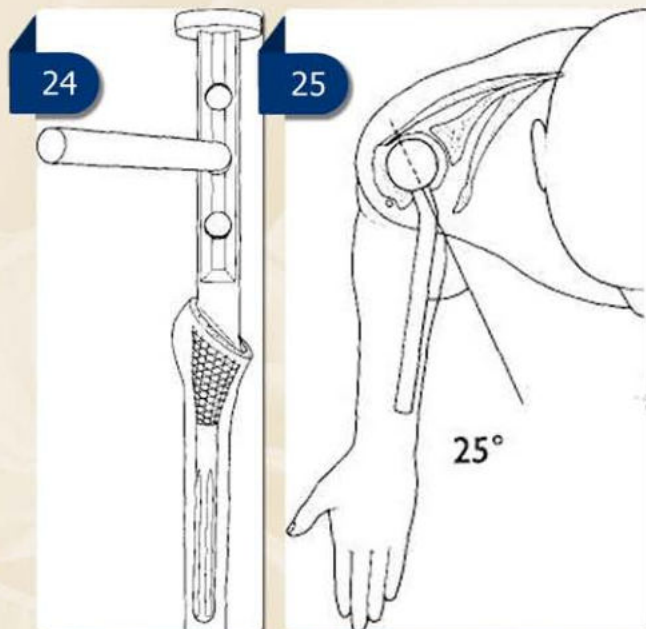
Prepare the humeral medullary canal using the **tapered reamers** (727-0021-006 - 727-0021-0012), increasing the size until resistance is felt throughout the length of the reamer. Start the reamer well laterally on the cut surface of the proximal humerus and ream straight down the humerus (23).

In some cases reaming is done from medial to lateral producing a varus alignment of the stem (23).



Shape the proximal humeral canal using the **humeral rasps** (727-0006-0006 - 727-0006-0012) (24).

Keeping the **alignment rod** (727-0011-0000) parallel with the forearm, retroversion is maintained using the alignment rod attached to the rasps (25).

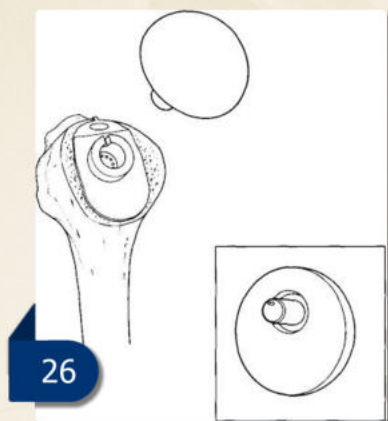


Insert the **trial humeral prosthesis** (727-0009-0006 - 727-0009-0012) into the medullary canal, the amount of retroversion must be maintained again by using the **alignment rod** (727-0011-0000) on the **humeral stem introducer** (727-0001-0001). If the trial is correctly orientated the articular surface of the implant should face directly toward the glenoid with the arm in the neutral position.

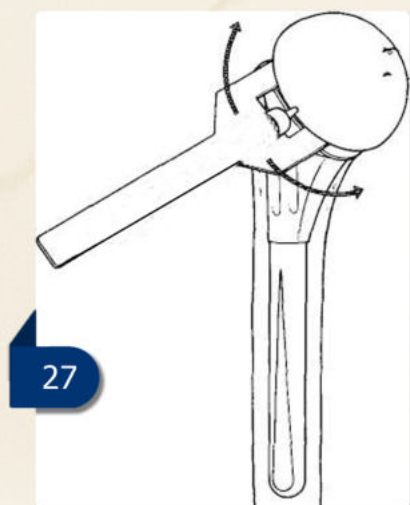
CHECKING THE POSITION OF THE COMPONENTS AND THE TENSION IN THE ROTATOR CUFF

Confirm the proper sizing of the prosthesis using the **modular head trials** (727-0009-4015 – 727-0009-4828). The size of trial head, which should be used first is best gauged with the surgeon's index finger. The shoulder is initially reduced without a trial head, place the index finger between the top of the stem and the glenoid.

If the finger can be comfortably inserted the shoulder will accept at least a 20 mm thick head, if not than chose a 17mm or 15mm head. An indexing facility is available on the humeral components to provide a 3 mm or 5 mm offset or concentric positions relative to the humeral axis (26).

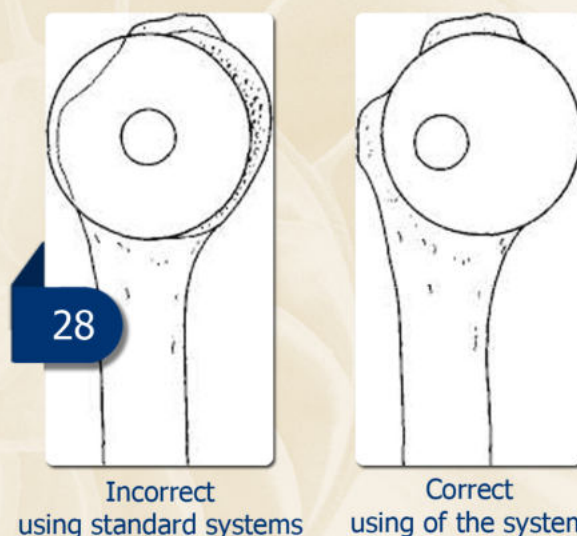


Place the humeral component onto the humeral stem, with the **fork** (727-0002-0001) placed between the head and stem (27).



Rotate the humeral head to identify the most suitable position to cover the cut surface of the humeral head and flush with the superior and posterior aspects of the head (28).

Remove the fork once the correct offset has been identified. With the modular trial head in place, the humeral head can be reduced and both the stability of the implant and the ability to close the subscapularis over the implant with the arm in external rotation can be tested. Reduce the joint carefully and if it is too tight, use a smaller humeral head trial with the same indexed offset.



CHECKING IMPLANT POSITION AND TENSIONING THE ROTATOR CUFF

The alignment of the glenoid component

If the glenoid component is correctly aligned a gap can be found between the greater tuberosity of the humerus and the acromion into, which it is possible to insert the surgeons little finger with some resistance felt. This confirms that the glenoid component has not been inserted facing upwards. The surgeon should also be able to insert his little finger between the tip of the coracoid and the front of the humeral head component. This confirms that the glenoid component has not been inserted in excessive anteversion.

Excessive tightness of the infraspinatus

Rotate the arm internally with the elbow in extension. The back of the hand should be able to touch the back of the ipsilateral buttock. If this is not possible, insert a smaller sized humeral head in the same rotational position as the trial.

Excessive tightness of the subscapularis

Pull the subscapularis taught and hold it against the front of the humeral head in the position, which it will adopt when repaired. By holding it in traction, the shoulder is now externally rotated with the elbow flexed to 90° but without any shoulder abduction. The surgeon observes, when and to what extent a gap between the subscapularis and its attachment develops. It is now possible to judge how much external rotation will be possible after surgery. It should be achieved at least 40° (preferably as much as 60°) of external rotation on the operating table.

Excessive laxity of the rotator cuff

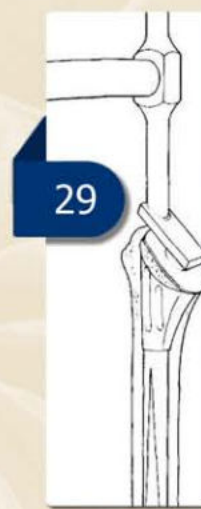The shoulder is held in neutral rotation and with the subscapularis detached the humeral head is pushed backwards. It should be possible to displace the humeral head backwards by 50% so that it sits just on the posterior glenoid rim. If it displaces more than this a larger humeral head height is required, if it displaces minimally then a smaller humeral head is required.

FINAL FIXATION OF THE HUMERAL STEM

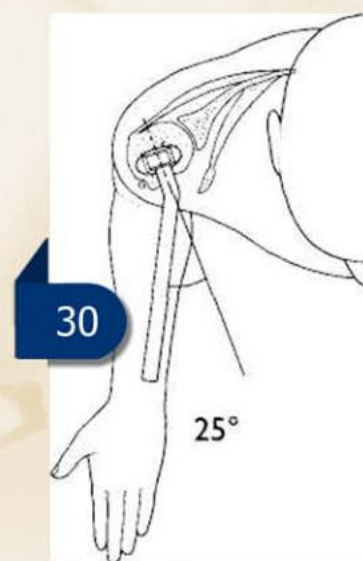
If the humeral component is being cemented select a stem one size smaller than the humeral reamer.

Attach the humeral implant to the humeral impactor/introducer (727-0001-0001) and place it in the medullary cavity.

After checking the alignment of the humeral stem, introduce the prosthesis into the humeral shaft until the appropriate level (29).



For a press fit implantation a stem is selected corresponding to the last used humeral rasp. The humeral stem is attached to the impactor (727-0001-0001) and driven in correct retroversion to its final position (30).

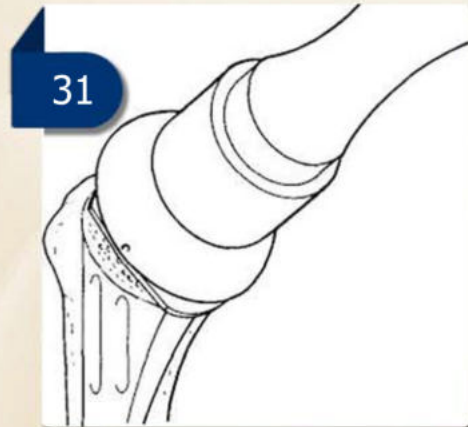


APPLICATION OF THE UNCEMENTED GLENOID BEARING

Change the glenoid insert trial now for the definitive glenoid insert. Carefully position it onto the base plate and impact it with one blow of the hammer on the **impactor** (727-0001-0003). Always check that there is no gap between the insert and the base plate.

HUMERAL HEAD INSERTION

When the appropriate head component has been established, impact the final implant component into place and impact the head with the **head impactor** (727-0001-0000) with a series of small blows (31). Take care to clean and dry properly both parts of the morsetaper before impaction. The shoulder is then reduced.



EXTRACTION

Important: by using the humeral stem extractor device (727-0002-0002) take care to first fix the humeral stem properly with the extractor, until it clicks in, only after that start fixing the screw of the extractor.